

## Cysteamine Toxicity in Patients with Cystinosis

Martine T. P. Besouw, MD, Richard Bowker, MA, MBBS, Jean-Paul Dutertre, MD, Francesco Emma, MD, William A. Gahl, MD, PhD, Marcella Greco, MD, Marc R. Lilien, MD, PhD, John McKiernan, MD, François Nobili, MD, Jerry A. Schneider, MD, PhD, Flemming Skovby, MD, PhD, Lambertus P. van den Heuvel, PhD, William G. Van't Hoff, MD, PhD, and Elena N. Levchenko, MD, PhD

**Objective** To report new adverse effects of cysteamine.

**Study design** Detailed clinical information was obtained from the patients' physicians.

**Results** New adverse events were reported in 8 of 550 patients with cystinosis treated with cysteamine in Europe during the last 5 years. Detailed clinical information was not available for 2 of these patients, 1 of whom died from cerebral ischemia. The 6 evaluable patients developed vascular elbow lesions (6/6), neurologic symptoms (1/6), bone and muscle pain (2/6), and/or skin striae (2/6). Analysis of biopsy specimens from the elbow lesions demonstrated angioendotheliomatosis with irregular collagen fibers. In 3 of the 6 patients, the daily cysteamine dose exceeded the recommended maximum of 1.95 g/m<sup>2</sup>/day. Dose reduction led to improvement of signs and symptoms in all 6 patients, suggesting a causal relationship with cysteamine administration.

**Conclusion** Cysteamine administration can be complicated by the development of skin, vascular, neurologic, muscular, and bone lesions. These lesions improve after cysteamine dose reduction. Doses >1.95 g/m<sup>2</sup>/day should be prescribed with great caution, but underdosing is not advocated. (*J Pediatr* 2011; ■: ■-■).

Cystinosis is an autosomal recessive metabolic disorder caused by mutations in the cystinosis, nephropathic (*CTNS*) gene encoding the lysosomal cystine carrier cystinosin.<sup>1</sup> The disease is characterized by lysosomal cystine accumulation and initially damages the kidneys, later affecting the eyes, endocrine organs, and neuromuscular system. Introduced in 1976,<sup>2</sup> cysteamine (USAN: cysteamine, INN: mercaptamine; Mylan Pharmaceuticals Inc, Morgantown, West Virginia) has proven efficacious for preserving renal function, enhancing growth,<sup>3</sup> and postponing extrarenal complications in patients with cystinosis.<sup>4,5</sup>

Until recently, the known side effects of oral cysteamine were limited to gastrointestinal complaints<sup>6,7</sup> and disagreeable breath and sweat odor.<sup>8</sup> Hyperthermia, lethargy, and rash were observed in the first treated patients but were not reported after gradual incremental dosing was instituted.<sup>9</sup>

During the last 5 years, Orphan Europe, a pharmaceutical company that markets and distributes cysteamine bitartrate (Cystagon) in Europe, received information on 8 of 550 patients (~1.5%) with cystinosis who developed new adverse events that had not been reported previously. Complete clinical information on 6 patients could be obtained and is presented in this article.

### Methods

Detailed information, including age at diagnosis of cystinosis, *CTNS* gene mutations, cysteamine dosage, white blood cell (WBC) cystine levels (measured in blood samples obtained 5-6 hours after the last cysteamine administration), adverse events and date of occurrence, further investigations, and follow-up, was collected from the patients' medical records by their physicians. (All cysteamine doses mentioned hereinafter refer to the amount of cysteamine free-base that was administered, regardless of the type of cysteamine salt used.)

Skin biopsy specimens from the bruise-like lesions were obtained in 5 of the 6 patients. The specimens were stained with hematoxylin and eosin and anti-CD34 immune stain and examined by light microscopy and electron microscopy.

BAPN	β-Aminopropionitrile
BSA	Body surface area
<i>CTNS</i>	gene encoding lysosomal cystine transporter cystinosin
MRI	Magnetic resonance imaging
PMN	Polymorphonuclear
WBC	White blood cell

From the Department of Pediatric Nephrology, Laboratory of Pediatrics (M.B., L.v.d.H., E.L.); University Hospitals Leuven, Leuven, Belgium; Department of Pediatric Nephrology, Derbyshire Children's Hospital, Derby, United Kingdom (R.B.); Orphan Europe, Puteaux, France (J-P.D.); Department of Nephrology and Urology, Bambino Gesù Children's Hospital and Research Institute, Rome, Italy (F.E., M.G.); Section on Human Biochemical Genetics, Medical Genetics Branch, National Human Genome Research Institute, National Institutes of Health, Bethesda, MD (W.G.); Department of Pediatric Nephrology, Wilhelmina Children Hospital Utrecht, Utrecht, The Netherlands (M.L.); Department of Pediatrics, Cork University Hospital, Wilton, Cork, Ireland (J.M.); Department of Pediatric Nephrology, University Hospital Besançon, Besançon, France (F.N.); Department of Pediatrics, University of California, San Diego, CA (J.S.); Department of Clinical Genetics, Juliane Marie Center, Copenhagen University Hospital, Copenhagen, Denmark (F.S.); Laboratory of Pediatrics and Neurology, UMC St Radboud, Nijmegen, The Netherlands (L.v.d.H.); and Nephro-Urology Unit, Institute of Child Health, University College London, London, United Kingdom (W.V.).

Supported by the Cystinosis Research Foundation. E.L. is supported by the Foundation for Scientific Research Flanders (grant 1801110N). The sponsors had no role in the study design; the collection, analysis and interpretation of data; the writing of the report; or the decision to submit the manuscript for publication. The authors declare no conflicts of interest.

0022-3476/\$ - see front matter. Copyright © 2011 Mosby Inc. All rights reserved. 10.1016/j.jpeds.2011.05.057

In 1 patient (case 4), the pharmacokinetics of cysteamine were studied and compared with those of 5 other patients with cystinosis who did not experience adverse drug effects. In all 6 patients, blood samples were obtained immediately before cysteamine administration (15 mg/kg cysteamine bitartrate) and every 60 minutes during the first 6 hours after cysteamine intake. Plasma cysteamine levels were measured as described previously.<sup>8</sup>

## Results

The **Table** presents clinical characteristics of the patients who experienced adverse events, along with detailed information on these adverse events, including neurologic symptoms, musculoskeletal weakness, skin striae primarily on the stretchable surfaces of the extremities, and bruise-like lesions of the elbows.

### Case Reports

Case 1 is a boy diagnosed with cystinosis and treated with cysteamine starting at age 2 years and 1 month. At age 5 years, he developed purple lesions on both elbows, more pronounced on the right elbow, with no history of trauma. Platelet count and coagulation screening results were normal. The cysteamine bitartrate dosage at that time was 120 mg/kg/day (2.9 g/m<sup>2</sup>/day). X-rays of both elbows revealed symmetrical periosteal reactions at the radial sides of the distal humeri. X-rays of both knees and ankles showed thickening of the trabecular bone in the distal femoral capital epiphysis, as well as in the proximal and distal epiphyses of the tibiae. Analysis of skin biopsy specimens demonstrated normal epidermis over a highly vascularized dermis. Vascular proliferation, with a marked increase in capillaries, was seen throughout the dermis, dissecting through collagen bundles and resembling (reactive) angioendotheliomatosis. Electron microscopy showed a normal epidermis overlying a dermis rich in collagen bundles and fibroblasts, with an intact basal lamina. The collagen bundles were randomly arranged and comprised structurally normal fibers. After the cysteamine dose was decreased to 73 mg/kg/day (2.0 g/m<sup>2</sup>/day), the purple color disappeared, although the skin overlying the elbows remained loose and wrinkly.

Case 2 is a boy treated with cysteamine starting at age 11 months. He was born at 35 weeks' gestation with a neonatal course complicated by birth asphyxia, respiratory distress syndrome, pneumothorax, and seizures. Surgery was performed at the age of 1 month to treat cricoid cartilage stenosis; he was diagnosed with hypothyroidism at the age of 10 months. At age 10 years, he developed leg and joint pain, bilateral knee valgus, severe scoliosis, muscle weakness, neuromotor regression, and dark red skin lesions on both elbows without any history of trauma (**Figure 1**, B). At that time, his dosage of cysteamine chlorohydrate was 90 mg/kg/day (2.4 g/m<sup>2</sup>/day). Brain magnetic resonance imaging (MRI) showed moderate reduction of white matter thickness, which was attributed to the perinatal asphyxia. Analysis of skin biopsy specimens from the elbow lesions revealed benign vascular proliferation

on light microscopy (**Figure 2**, A and B) and clear abnormalities of elastin fibers and some collagen fibers, with increased variability of collagen fiber caliber, on electron microscopy (**Figure 2**, C and D). Because the exact etiology of the elbows lesions was unknown, they were surgically removed; however, they relapsed. Eighteen months after the patient's first presentation, he developed red striae on both thighs (**Figure 1**, A). One month later he was hospitalized with asthenia, vomiting, behavioral disturbances (ie crying, agitation, sleeping disorders, confusion), and severe muscle weakness, making him unable to walk. Electroencephalography and brain MRI showed no significant changes compared with previous findings. Bone densitometry showed a z-score of -1.3. The patient was switched from cysteamine chlorohydrate to cysteamine bitartrate, and the total dosage of cysteamine free-base was decreased to 40 mg/kg/day (0.9 g/m<sup>2</sup>/day). He demonstrated clinical improvement in the ensuing months, including waning of the neurologic symptoms and increased muscle strength; however, his abnormal walking pattern persisted because of severe knee deformities, despite maximized phosphate and vitamin D supplementation, necessitating orthopedic surgery to realign his lower limbs. Remarkably, a bone callus did not develop until several months after surgery, which prevented removal of the external pins and fixator for more than 1 year.

Case 3 is a boy diagnosed with cystinosis and treated with cystamine (a disulfide of cysteamine) starting at age 1 year and 1 month. At age 14 years, he developed blue discoloration and easy bruising of the extensor surface of both elbows (**Figure 1**, C). At that time, his dosage of cysteamine free-base, prescribed as cystamine, was 71 mg/kg/day (2.2 g/m<sup>2</sup>/day). Platelet count and coagulation screening results were normal. Skin biopsy specimens were not obtained. Cysteamine bitartrate was added to the treatment, and the total dosage of cysteamine free-base was lowered to 56 mg/kg/day (1.8 g/m<sup>2</sup>/day). The swelling and dark blue discoloration subsided over 2-3 months and did not recur, but the skin overlying the elbows remained wrinkly and darker.

Case 4 is a boy diagnosed with cystinosis and treated with cysteamine starting at age 11 months. At age 15 years, he developed red striae on his upper legs and abdomen and a soft, cushion-like lesion on the stretchable surface of his left elbow. At that time, his prescribed cysteamine bitartrate dosage was 48 mg/kg/day (1.7 g/m<sup>2</sup>/day), although his parents admitted that they administered higher doses of 54 mg/kg/day (1.9 g/m<sup>2</sup>/day) on occasion. Platelet count and coagulation screening results were normal. X-rays of the lower extremities did not show any abnormalities. X-rays of the left wrist showed a delay in bone age of 2 years with no other abnormalities. Bone densitometry of the lumbar spine and both hips by dual emission X-ray absorptiometry showed a z-score of -1.8. Analysis of skin biopsy specimens from the elbow lesions revealed dilated capillaries in the dermis and an increased number of lymphocytes. Deeper in the dermis there was a space lined by flattened cells. Brain MRI detected no abnormalities. Cysteamine plasma levels and area under the curve after the administration of 15 mg/kg cysteamine

**Table.** Clinical characteristics of the patients with cystinosis and details of adverse events

Patient	Sex	Age at diagnosis, months	CTNS gene mutation	Age at onset of adverse event, years	GFR, mL/min/1.73 m <sup>2</sup> *	Cystinosis treatment, daily dosage <sup>†</sup>	Concomitant medications	Description of adverse event	Follow-up
1	M	25	57kb del	5	87	120 mg/kg <sup>‡</sup> 2.9 g/m <sup>2</sup>	Indomethacin, L-carnitine, L-thyroxine, potassium citrate, somatotropin	- Purpuric lesions on elbows (right > left)	- Recovery after dose reduction
2	M	11	c.18-21 del c.18-21 del	10	62	90 mg/kg <sup>§</sup> 2.4 g/m <sup>2</sup>	Calcitriol, epoietin beta, folic acid, hydrochlorothiazide, l-carnitine, l-thyroxine, phosphate, sodium bicarbonate citrate, sodium chloride, somatotropin	- Sensorimotor disorder (severe asthenia, attention deficit, personality disorder) - Leg and joint pain (muscle weakness, inability to walk), bilateral knee valgus, scoliosis - Dark-red skin lesions on both elbows	- Relapse of skin lesions after surgical removal without dose reduction - Recovery of neurologic symptoms after dose reduction - Partial recovery of leg and joint pain after dose reduction, persistent bilateral knee valgus - Recovery after dose reduction
3	M	13	57kb del 57kb del	14	30	71 mg/kg <sup>¶</sup> 2.2 g/m <sup>2</sup>	Alphacalcidol, citrate, esomeprazol, l-thyroxine, phosphate, potassium chloride, somatotropin	- Bluish discoloration and bruising of elbows	- Recovery after dose reduction
4	M	11	57kb del 57kb del	15	101	56 mg/kg <sup>‡</sup> 1.7 g/m <sup>2</sup>	Alphacalcidol, iron, potassium bicarbonate, sodium potassium phosphate, somatotropin	- Mild skin striae (upper legs, abdomen) - Soft cushion-like lesions on left elbow	- Recovery after dose reduction
5	M	26	57kb del 57kb del	7	67	48 mg/kg <sup>‡</sup> 1.3 g/m <sup>2</sup>	Alphacalcidol, indomethacin, l-carnitine, nicardipine, phosphoric acid, potassium, sodium bicarbonate	- Mild elbow blood accumulation - Leg and joint pain, severe osteoporosis	- Relapse without dose reduction, followed by spontaneous recovery - Persistent leg and joint pain
6	M	9	c.18-21 del c.18-21 del	3	73	59 mg/kg <sup>‡</sup> 1.2 g/m <sup>2</sup>	Alphacalcidol, potassium chloride bicarbonate, sodium bicarbonate	- Elbow bruising, increased stretching of the skin	- Spontaneous recovery, relapse after increasing dose, recovery after dose reduction

GFR, glomerular filtration rate.

\*All patients had renal Fanconi syndrome.

<sup>†</sup>Doses are reported as cysteamine free-base.

<sup>‡</sup>Patient was treated with cysteamine bitartrate.

<sup>§</sup>Patient was treated with cysteamine chlorhydrate.

<sup>¶</sup>Patient was treated with cystamine.

bitartrate did not differ from those in the 5 patients with cystinosis without adverse events (data not shown). The parents were instructed to administer cysteamine as prescribed, and the lesions diminished thereafter. The skin overlying the elbows remained loose and wrinkly, however.

Case 5 is a boy diagnosed with cystinosis and treated with cysteamine starting at age 2 years and 2 months. At age 7 years, he developed bruises on both elbows. At that time, his cysteamine bitartrate dosage was 48 mg/kg/day (1.3 g/m<sup>2</sup>/day). The lesions initially disappeared, but recurred after 4 months. Light microscopy analysis of a skin biopsy specimen revealed vascular proliferation. The lesions disappeared once again, leaving behind scarring on both elbows. Within 2 months, the patient experienced another relapse of the elbow lesions, which again recovered spontaneously. During the same period, he developed severe osteoporosis and bone pain and became limited in all activities, including walking. The latter symptoms had not yet subsided at the time of this report.

Case 6 is a boy diagnosed with cystinosis and treated with cysteamine starting at age 9 months. At age 3 years, he developed bruises on both elbows shortly after his dosage of cysteamine bitartrate had been increased to 59 mg/kg/day (1.2 g/m<sup>2</sup>/day). X-rays revealed no abnormalities. The skin lesions disappeared spontaneously, but relapsed several years after the dosage of cysteamine bitartrate was again increased to 59 mg/kg/day (1.5 g/m<sup>2</sup>/day). Light microscopy of skin biopsy specimens from the relapsed elbow lesions revealed

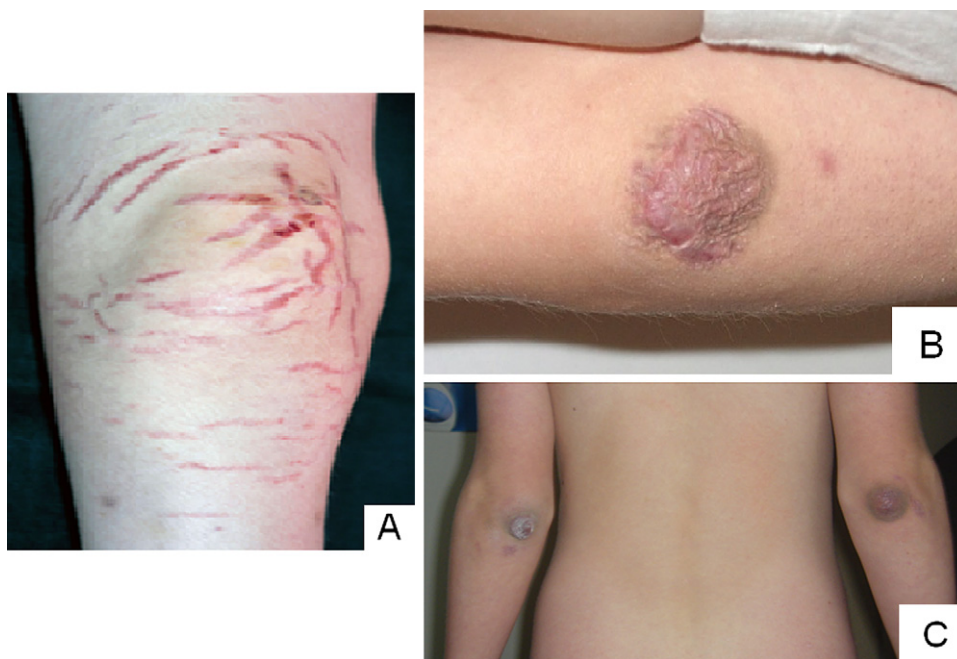
angioendotheliomatosis. After the cysteamine dosage was decreased, the lesions disappeared once again; however, the skin overlying the elbows remained loose and wrinkly.

## Discussion

We have reported some newly recognized side effects of cysteamine. In all of our patients, the skin lesions and neurologic symptoms diminished or disappeared after the cysteamine dosage was reduced. In 1 of the 2 patients with bone and muscular pain, these symptoms decreased in response to a cysteamine dose reduction. In patient 6, skin lesions relapsed after the cysteamine dose was increased. Based on these findings, we suggest that cysteamine plays a causative role in these symptoms, although the mechanistic explanation is still lacking.

Two additional related patients have been reported in international conferences. The most dramatic course was seen in a patient who died from cerebral ischemia<sup>10,11</sup>; unfortunately, no further details were available for this patient. Neurologic symptoms and stroke have been reported in patients with cystinosis both on and off cysteamine treatment<sup>12,13</sup>; thus, whether cysteamine was responsible for the fatal outcome in the aforementioned patient remains unclear.

Skin biopsy specimens obtained from the elbow lesions of all patients except patient 3 exhibited vascular proliferation, resembling angioendotheliomatosis, which is characterized by endothelial and myoepithelial cell proliferation within



**Figure 1.** Skin manifestations of cysteamine toxicity. **A**, Skin striae at the stretchable surface of the knee of patient 1. **B**, Bruise-like lesion at the elbow of patient 2. The lesion is starting to go into regression, the skin is becoming loose and wrinkly. **C**, Bruise-like lesions on both elbows of patient 3. The lesions are more recent compared with those shown in **B**, and the skin is still tight and dark-purple.

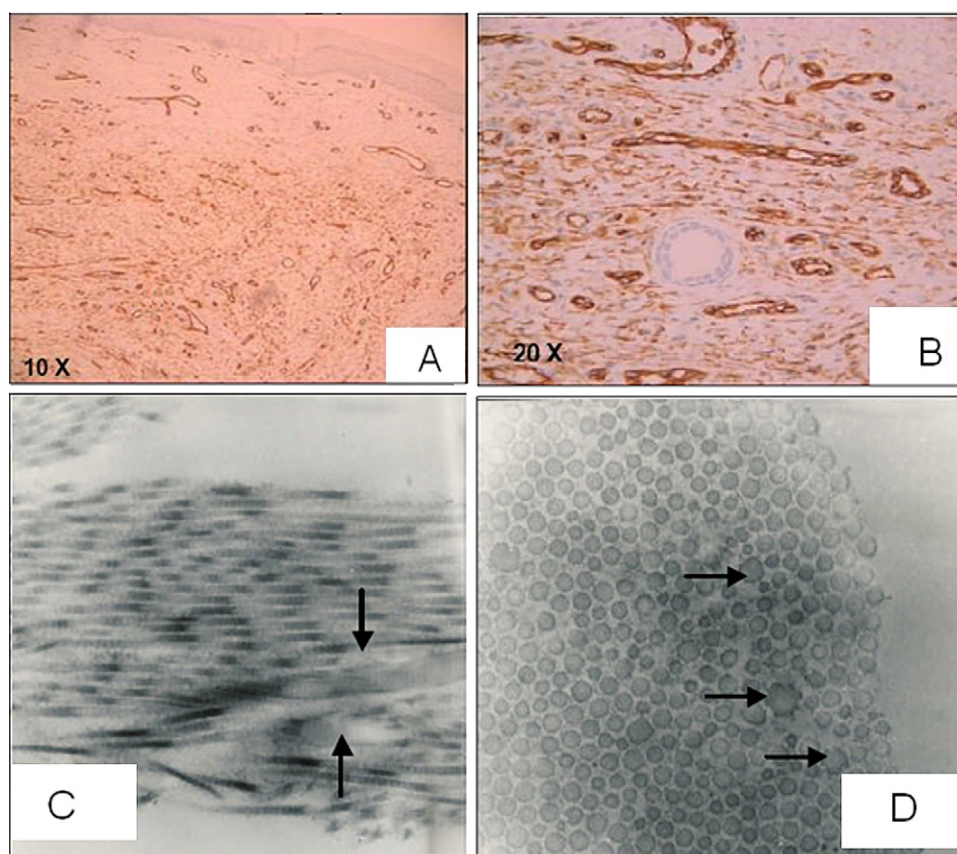
the blood vessel lumina. Angioendotheliomatosis can be either benign or reactive, or may represent a neoplastic and malignant tumor. The malignant variant is classified as an intravascular malignant lymphoma and is currently termed “intravascular lymphomatosis.” The benign or reactive variant, which most closely fits our patients’ histological findings, involves nondegenerative lesions restricted to intravascular proliferation of endothelial cells.<sup>14,15</sup>

Electron microscopy revealed randomly arranged collagen fibers with variable diameters resembling the features typically observed in Ehlers-Danlos syndrome.<sup>16,17</sup> Hypothetically, cysteamine might interfere with interstitial matrix proteins in some patients and promote angiogenesis, possibly leading to the development of reactive angioendotheliomatosis. The specific location of these lesions at the external aspects of the elbows suggests that minor skin trauma enhances this phenomenon. Interestingly, rats treated with cysteamine 50 mg/kg/day for 6 months developed severe skeletal deformities resembling the lesions in our patients, as well as cardiovascular abnormalities, including dissecting aneurysm of the thoracic aorta.<sup>18</sup> The investigators hypothesized that these abnormali-

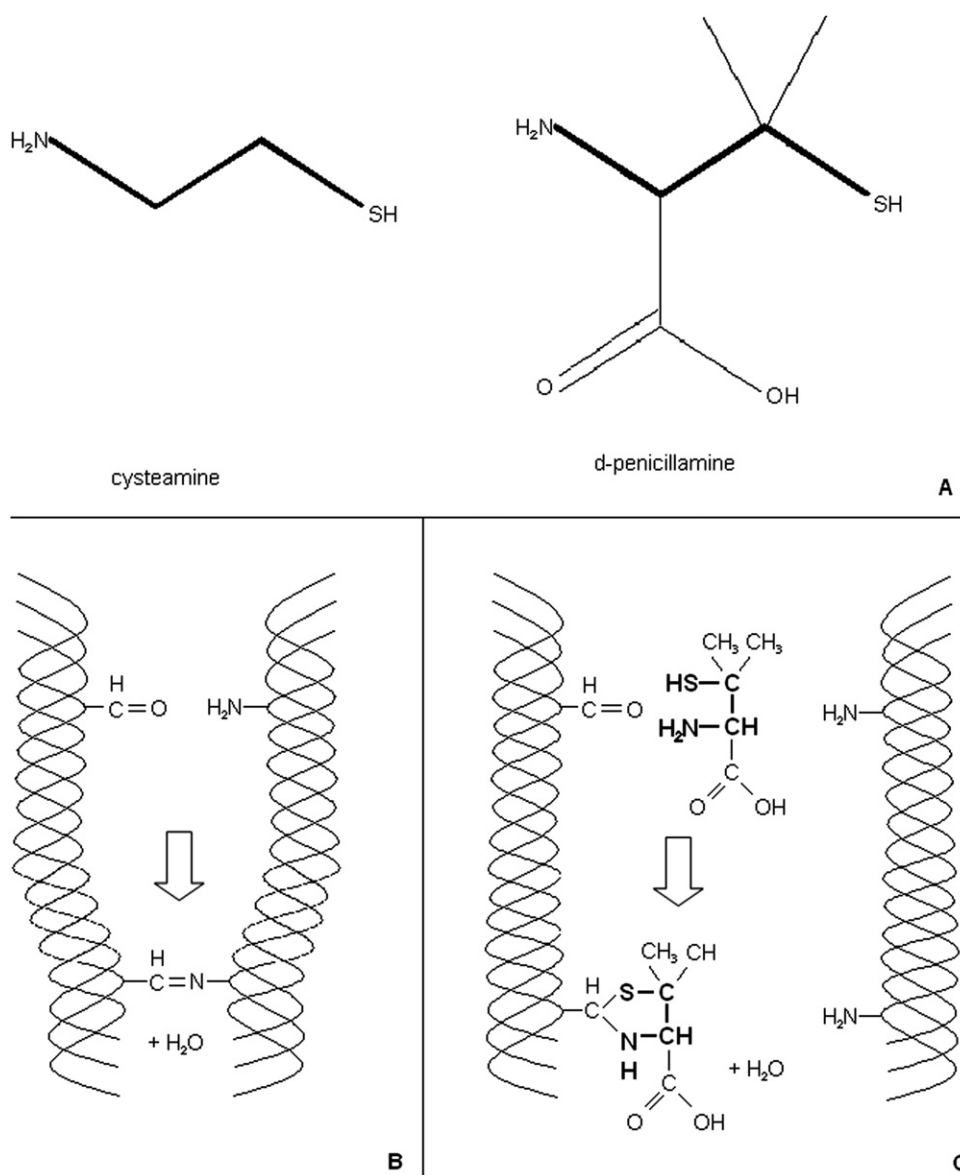
ties might be caused by deficient cross-linking of elastin fibers, which are present in the highest concentrations in the aorta and cardiovascular tissues.<sup>18</sup>

The symptoms described here also resemble those of osteolathyrism. This condition is caused by intoxication with  $\beta$ -aminopropionitrile (BAPN), which is found in several *Lathyrus* peas. BAPN irreversibly inhibits the function of the enzyme lysyl oxidase, which facilitates the formation of aldehydes on both collagen and elastin molecules that are necessary for collagen cross-link formation.<sup>19,20</sup> Taurine, a degradation product of cysteamine,<sup>21</sup> can increase BAPN toxicity.<sup>22</sup>

The interaction of collagen and D-penicillamine, a drug with structural similarities to cysteamine (Figure 3, A), has been studied extensively. D-penicillamine prevents newly synthesized collagen fibers from forming stable cross-links through binding of the carbon present in aldehydes to its -SH and -NH<sub>2</sub> groups (Figure 3, B and C). These aldehydes are thus no longer available for cross-link formation, resulting in collagen fibers of lower strength, resembling osteolathyrism.<sup>19,20</sup> Experiments comparing the effects on collagen cross-linking of several amino thiols, including



**Figure 2.** Skin biopsy results of the bruise-like lesion in patient 2. **A** and **B**, Light microscopy, anti-CD34 immunostaining showing normal epidermis overlying a benign vascular proliferation in the dermis. **A**, Newly formed vessels show dilated lumen in the superficial dermis and become smaller in the deep dermis/hypodermis. Plump CD34<sup>+</sup> endothelial cells line numerous vascular structures, some of them completely developed and others with immature features; a few thin-walled vessels are also present. **B**, The CD34<sup>-</sup> sweat gland epithelium serves as negative control. Electron microscopy showing variable collagen fiber caliber, with focal diameter increases (arrows) in **C**, longitudinal and **D**, transversal cuts.



**Figure 3.** Influence of D-penicillamine and cysteamine on collagen cross-linking. **A**, Chemical structures of cysteamine and D-penicillamine. **B**, Normal cross-linking in collagen. The aldehyde on the left triple helix binds to the -NH<sub>2</sub> group of the right triple helix, resulting in a strong cross-link. D-penicillamine binds to the aldehyde of the left triple helix, preventing it from forming a cross-link with another triple helix. **C**, The same type of interaction between cysteamine (*bold type*) and the aldehyde group is expected.

cysteamine, showed that the effect of cysteamine was comparable to that of D-penicillamine.<sup>19</sup> The fact that extensive cross-linking is of particular importance in skin and bone<sup>19</sup> could further explain why our patients exhibited both skin and bone problems. The overlap in mode of action between cysteamine and D-penicillamine is further illustrated by a case report of a child with cystinuria treated with D-penicillamine who developed side effects comparable to the adverse events reported in our 6 patients with cystinosis (ie, flat feet, scoliosis, pectus carinatum, hypermobility of joints, molluscoid pseudotumors, and atrophic scarring).<sup>23</sup> The effect of drugs on collagen involving mainly the

prevention of cross-link formation in newly formed collagen fibers, not the disruption of already existing cross-links,<sup>24</sup> could explain why all of the patients reported here are children, given that collagen production decreases with age.<sup>25</sup> This hypothesis is further supported by the fact that the effect of D-penicillamine in rats is most evident in young animals.<sup>19,26</sup>

The question remains as to why only a small proportion of patients develop symptoms of cysteamine toxicity. Initially, we suggested that differences in pharmacokinetics might increase cysteamine plasma levels in some patients. Despite being limited to one subject, our data do not support this

hypothesis. However, a possible increase in tissue cysteamine concentrations in susceptible patients due to differences in cysteamine transport or metabolism, cannot be ruled out.

Surprisingly, all patients reported to date are from Europe. The cysteamine bitartrate distributed in Europe and the United States is produced by the same manufacturer; thus, geographic differences cannot be explained by differences in cysteamine formulation. Nonetheless, the possibility that these symptoms are underdiagnosed in North America cannot be excluded. Soon after the first reports, Orphan Europe actively informed all European physicians who prescribe cysteamine of these possible severe adverse events, including the neurological abnormalities and the case with fatal outcome, which has led to reports of additional cases. We hope that the present report will further increase physicians' awareness worldwide. Other potential reasons for geographic differences include differences in calculating drug doses (per kg of body weight vs per m<sup>2</sup> of body surface area [BSA]) and the concomitant use of other medications that could influence cysteamine metabolism. Epidemiologic data collected by recently established cystinosis registries in Europe and North America will provide useful information in the near future.

Cysteamine remains the only available treatment for cystinosis. Over the past several decades, several salts of cysteamine have been used; the most recent and widely used form, cysteamine bitartrate, has been marketed in Europe by Orphan Europe since 1997. The originally recommended dose was 50 mg/kg/day (1.30 g/m<sup>2</sup>/day) for children aged <12 years or weighing <50 kg and 2 g/day for patients aged >12 years or weighing >50 kg, with a maximum dose of 90 mg/kg/day (1.95 g/m<sup>2</sup>/day). Daily doses are administered in 4 equal portions every 6 hours and refer to the amount of cysteamine free-base prescribed. The aim is to administer cysteamine doses sufficient to achieve WBC cystine levels <1 nmol ½ cystine/mg protein, as has been advocated for maximum renal and extrarenal protection. Although the extent to which WBC cystine content reflects renal and extrarenal cystine accumulation is unknown, the use of higher cysteamine doses, especially when calculated in g/m<sup>2</sup>/day, has been reported to protect against renal function deterioration.<sup>27</sup> Furthermore, the determination of cystine levels in polymorphonuclear (PMN) cells instead of mixed leukocytes can lead to higher cystine values, because cystine preferentially accumulates in PMN cells compared with other WBCs, including lymphocytes. Thus, switching from cystine measurements in mixed WBCs to PMN cells will result in slightly different reference values and can necessitate cysteamine dose adjustment.<sup>28</sup> In the present study, cystine was measured in mixed WBCs in patients 1, 3, 5 and 6 and in PMN cells in patients 2 and 4. Each laboratory provided its own reference values for healthy carriers and noncarriers. In all patients with cystinosis receiving cysteamine treatment, efforts were made to keep cystine levels within the carrier range.

In children, the body weight-to-BSA ratio increases with age, resulting in higher daily doses of the drugs, when these are calculated per kg of body weight compared with those calculated per m<sup>2</sup> of BSA in preadolescent and adolescent

patients. In response to reports of the first cases of cysteamine toxicity, and considering the causal relationship between cysteamine dose and adverse events, Orphan Europe organized a team of experts that recommended calculating the dose based on BSA and avoiding doses exceeding 1.95 g/m<sup>2</sup>/day. Based on our experience, we recommend a cysteamine dose reduction (~25%), with careful monitoring of WBC cystine levels, in patients presenting with cutaneous lesions. In patients with a sudden onset of neuromuscular symptoms, we advise discontinuing cysteamine administration until symptoms resolve. All patients presenting with cysteamine adverse events should be reported to the pharmaceutical company responsible for the drug's distribution, which in turn will contact the experts for further recommendations. ■

Submitted for publication Nov 17, 2010; last revision received May 4, 2011; accepted May 31, 2011.

Reprint requests: Elena N. Levchenko, MD, PhD, Department of Pediatric Nephrology, University Hospital Gasthuisberg, Herestraat 49, 3000 Leuven, Belgium. E-mail: elena.levchenko@uzleuven.be

## References

1. Town M, Jean G, Cherqui S, Attard M, Forestier L, Whitmore SA, et al. A novel gene encoding an integral membrane protein is mutated in nephropathic cystinosis. *Nat Genet* 1998;18:319-24.
2. Thoene JG, Oshima RG, Crawhall JC, Olson DL, Schneider JA. Cystinosis: intracellular cystine depletion by aminothiols in vitro and in vivo. *J Clin Invest* 1976;58:180-9.
3. Markello TC, Bernardini IM, Gahl WA. Improved renal function in children with cystinosis treated with cysteamine. *N Engl J Med* 1993;328:1157-62.
4. Kimonis VE, Troendle J, Rose SR, Yang ML, Markello TC, Gahl WA, et al. Effects of early cysteamine therapy on thyroid function and growth in nephropathic cystinosis. *J Clin Endocrinol Metab* 1995;80:3257-61.
5. Gahl WA, Balog JZ, Kleta R. Nephropathic cystinosis in adults: natural history and effects of oral cysteamine therapy. *Ann Intern Med* 2007; 147:242-50.
6. Dohil R, Fidler M, Barshop B, Newbury R, Sellers Z, Deutsch R, et al. Esomeprazole therapy for gastric acid hypersecretion in children with cystinosis. *Pediatr Nephrol* 2005;20:1786-93.
7. Dohil R, Newbury RO, Sellers ZM, Deutsch R, Schneider JA. The evaluation and treatment of gastrointestinal disease in children with cystinosis receiving cysteamine. *J Pediatr* 2003;143:224-30.
8. Besouw M, Blom H, Tangerman A, De Graaf-Hess A, Levchenko E. The origin of halitosis in cystinotic patients due to cysteamine treatment. *Mol Genet Metab* 2007;91:228-33.
9. Corden BJ, Schulman JD, Schneider JA, Thoene JG. Adverse reactions to oral cysteamine use in nephropathic cystinosis. *Dev Pharmacol Ther* 1981;3:25-30.
10. Besouw MTP, Van den Heuvel LP, Dutertre JP, Awan A, Van't Hoff WG, Cornelissen EAM, et al. Cysteamine toxicity in cystinosis patients [abstract]. *Pediatr Nephrol* 2010;25:1822.
11. Besouw MTP, Van den Heuvel LP, Dutertre JP, Awan A, Van't Hoff WG, Cornelissen EAM, et al. Cysteamine toxicity in cystinosis patients and cultured human cells [abstract]. *Pediatr Nephrol* 2010;25:2197-8.
12. Greco M, Brugnara M, Zaffanello M, Taranta A, Pastore A, Emma F. Long-term outcome of nephropathic cystinosis: a 20-year single-center experience. *Pediatr Nephrol* 2010;25:2459-67.
13. Van Lierde A, Colombo D, Rossi LN, Marchesi F, Giani M, Consalvo, et al. Hemiparesis in a girl with cystinosis and renal transplant. *Eur J Pediatr* 1994;153:702-3.
14. Broyer M, Tete MJ, Guest G, Bertheleme JP, Labrousse F, Poisson M. Clinical polymorphism of cystinosis encephalopathy: results of treatment with cysteamine. *J Inher Metab Dis* 1996;19:65-75.

15. Wick MR, Rocamora A. Reactive and malignant "angioendotheliomatosis": a discriminant clinicopathological study. *J Cutan Pathol* 1988;15:260-71.
16. Rongioletti F, Rebora A. Cutaneous reactive angiomatoses: patterns and classification of reactive vascular proliferation. *J Am Acad Dermatol* 2003;49:887-96.
17. Vogel A, Holbrook KA, Steinmann B, Gitzelmann R, Byers PH. Abnormal collagen fibril structure in the gravis form (type I) of Ehlers-Danlos syndrome. *Lab Invest* 1979;40:201-6.
18. Malfait F, De Paepe A. Molecular genetics in classic Ehlers-Danlos syndrome. *Am J Med Genet C (Semin Med Genet)* 2005;139C:7-23.
19. Jayaraj AP. Dissecting aneurysm of aorta in rats fed with cysteamine. *Br J Exp Pathol* 1983;64:548-52.
20. Nimni ME. Mechanism of inhibition of collagen cross-linking by penicillamine. *Proc R Soc Med* 1977;70(Suppl 3):65-72.
21. Barrow MV, Simpson CF, Miller EJ. Lathyrism: a review. *Q Rev Biol* 1974;49:101-28.
22. Cavallini D, Scandurra R, Demarco C. The enzymatic oxidation of cysteamine to hypotaurine in the presence of sulfide. *J Biol Chem* 1963;238:2999-3005.
23. McDonald BE, Bird HR, Strong FM. Effects of amino acids and related compounds on aortic aneurysms in turkeys. *Proc Soc Exp Biol Med* 1963;113:728-32.
24. Steinmann B, Otten A, Gitzelmann R. Skin and bone lesions (dermatosteolathyrism), possible side effects of D-penicillamine treatment, in a boy with cystinuria. *Helv Paediatr Acta* 1979;34:281-91.
25. Klein L, Nowacek CJ. Effect of penicillamine on new and pre-existing (3H) collagen in vivo. *Biochim Biophys Acta* 1969;194:504-12.
26. Varani J, Dame MK, Rittie L, Fligel SE, Kang S, Fisher GJ, et al. Decreased collagen production in chronologically aged skin: roles of age-dependent alteration in fibroblast function and defective mechanical stimulation. *Am J Pathol* 2006;168:1861-8.
27. Nimni ME. A defect in the intramolecular and intermolecular cross-linking of collagen caused by penicillamine, I: metabolic and functional abnormalities in soft tissues. *J Biol Chem* 1968;243:1457-66.
28. Levchenko E, de Graaf-Hess A, Wilmer M, van den Heuvel L, Monnens L, Blom H. Comparison of cystine determination in mixed leukocytes vs polymorphonuclear leukocytes for diagnosis of cystinosis and monitoring of cysteamine therapy. *Clin Chem* 2004;50:1686-8.