

Genetic basis of cystinosis in Turkish patients: a single-center experience

Rezan Topaloglu · Thierry Vilboux · Turgay Coskun · Fatih Ozaltin · Brad Tinloy · Meral Gunay-Aygun · Aysin Bakkaloglu · Nesrin Besbas · Lambert van den Heuvel · Robert Kleta · William A. Gahl

Received: 17 October 2010 / Revised: 28 April 2011 / Accepted: 1 June 2011
© IPNA 2011

Abstract We report the molecular findings for the *CTNS* gene in 12 Turkish cystinosis patients aged 7–29 years. All presented initially with severe failure to thrive, polyuria, and polydipsia. Cystinosis was diagnosed at age 1 month to 9 years. Seven patients reached end-stage renal failure at ages ranging from 6.5 to 15 years. Whereas three of the remaining five have renal Fanconi syndrome with proteinuria, two have had kidney failure of varying degrees. Molecular analyses involved an initial multiplex polymerase chain reaction (PCR) to determine the presence or absence of the 57-kb northern European founder deletion in *CTNS*, followed by sequencing of the ten coding exons of *CTNS*. Comprehensive mutation analysis verified that none of the 12 patients carried the common 57-kb deletion. We identified four previously reported nucleotide variations associated with cystinosis and five new variants: a 10-kb deletion, three missense variants, and a nucleotide substitution in a

potential branch point site of intron 4. This study is the first molecular analysis of Turkish cystinosis patients and provides guidance for the molecular diagnosis of cystinosis in this population.

Keywords Cystinosis · *CTNS* gene · Turkish patients · Genetic basis · New mutations

Introduction

Cystinosis (*CTNS*; OMIM 219800) is an autosomal recessive disease caused by mutations of the *CTNS* gene (OMIM 606272; GenBank NM_004937.2) located on chromosome 17p13. *CTNS* codes for cystinosin, a protein that facilitates cystine egress from lysosomes. Defective lysosomal transport leads to widespread accumulation and crystallization of cystine in many organs, particularly the kidney, cornea, bone marrow, thyroid, lymph nodes, liver, and spleen [1–3]. The most common and severe phenotype is infantile nephropathic cystinosis in which renal signs and symptoms predominate; patients develop renal Fanconi syndrome in infancy and renal failure in the first decade. Other organs frequently affected are the cornea, causing painful photophobia, and the thyroid, associated with hypothyroidism. Myopathy, swallowing, pulmonary dysfunction, diabetes, male hypogonadism, and central nervous system involvement are seen in adolescents and young adults with nephropathic cystinosis [1, 4]. A milder cystinosis phenotype presents in adolescence with more slowly progressive renal failure and ocular disease, and an adult form (i.e., ocular) presents with only corneal disease [1, 5].

Management and treatment of infantile nephropathic cystinosis includes supportive treatment to maintain fluid and electrolyte balance in infancy and early childhood.

R. Topaloglu (✉) · F. Ozaltin · A. Bakkaloglu · N. Besbas
Dept of Pediatric Nephrology,
Hacettepe University Faculty of Medicine,
Ankara 06100, Turkey
e-mail: rezantopaloglu@hacettepe.edu.tr

T. Vilboux · B. Tinloy · M. Gunay-Aygun · R. Kleta · W. A. Gahl
NIH, NHGRI, MGB,
Bldg. 10, Rm. 10 C107, 10 Center Drive,
Bethesda, MD 20892, USA

T. Coskun
Department of Pediatric Metabolic Diseases,
Hacettepe University Faculty of Medicine,
Ankara 06100, Turkey

L. van den Heuvel
Department of Pediatrics Academic Hospital Leuven,
Herestraat 49,
3000 Leuven, Belgium

Early diagnosis and specific treatment with orally administered cysteamine delays the onset of renal failure and prevents the occurrence of other serious organ involvement [6, 7]. Cysteamine eye drops may lessen visual symptoms by dissolving the corneal cystine crystals. Hemodialysis (HD), continuous ambulatory peritoneal dialysis (CAPD), and renal transplantation (Tx) are associated with increased survival rates in patients who progressed to end-stage renal failure (ESRF). Cystine accumulation has been reported in transplanted kidneys but with no clinical manifestations, as it reflects invasion of host cells containing cystine. However, after renal Tx, extrarenal manifestations of cystinosis continue to occur [1].

The *CTNS* gene consists of 12 exons; numbers 3–12 are coding exons. *CTNS* mutations result in either complete abolition of, or reduced cystine transport [1, 5]. Many different mutations have been identified throughout the entire gene in European and American cystinosis patients [8–18]. The most common mutation is a large 57-kb deletion [11, 13–16]. Here we report *CTNS* mutation analysis of 12 Turkish patients with cystinosis, representing the first such molecular diagnosis of cystinosis in this population.

Materials and methods

Patients

We studied 12 Turkish patients who were diagnosed with cystinosis and followed at Hacettepe University Faculty of Medicine Children’s Hospital Department of Pediatric Nephrology and Metabolic Diseases Unit. Informed consent was obtained from the patients and/or their parents. Blood samples were collected from all patients; DNA was extracted from leukocytes, as previously described [19].

Molecular analysis

The 57-kb deletion was tested using the method previously described [20]. Primers were designed to amplify the ten coding exons of *CTNS*, including their intronic boundaries (primer sequences available on request). Standard polymerase chain reaction (PCR) amplification procedures were employed. All PCR amplified products were directly sequenced using the Big Dye 3 Terminator chemistry (Applied Biosystems) employing an ABI 3130xl genetic analyzer (Applied Biosystems). Data were analyzed using Sequencher 4.8 (Gene Codes Corporation).

Mutation prediction analysis

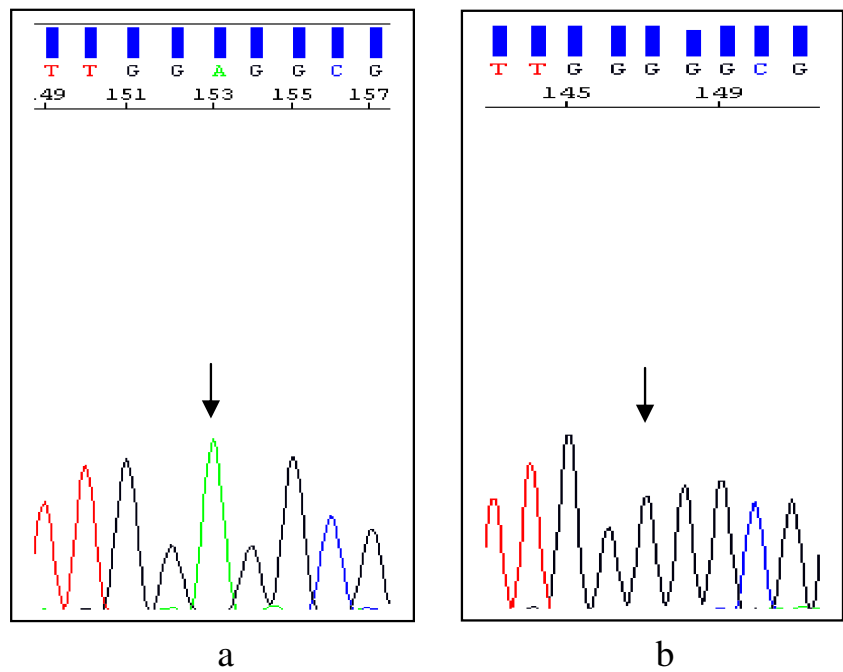
The effect of missense variants and potential splice-site variants was evaluated, as described previously [21].

Table 1 Clinical data and *CTNS* variants^a of the patients

Patient	Age (years)	Sex	Age at diagnosis (months)	Consanguinity	Sibling disease	Renal status	RRT	<i>CTNS</i> variant allele 1	<i>CTNS</i> variant allele 2	Other
TR1	12	M	15	No	No	Proteinuria		c.451A>G;p.R151G	c.1015 G>A;p.G339R	rs222753 (h)
TR2	11	M	9	Yes	No	Proteinuria		c.18_21del[GACT;p.T7X7	c.18_21del[GACT;p.T7FX7	rs222753 (H)
TR3	16	M	12	No	No	ESRD at age 9	CAPD, HDTx, HD	c.62-1083_c.551del10217	c.62-1083_c.551del10217	rs161400 (H)
TR4	21.5	M	12	Yes	Yes	ESRD at age 9.5	CAPD, HD	c.141-22a>g	c.681 G>A; p.E227E	rs1800528 (h), rs222753(h)
TR5	17.5	M	1	Yes	Sib of TR4	RI		c.141-22a>g	c.681 G>A; p.E227E	rs1800528 (h), rs222753(h)
TR6	15.5	F	12	Yes	No	Proteinuria		c.518A>G; p.Y173C	c.518A>G; p.Y173C	
TR7	25.5	M	105	Yes	No	RI		c.451A>G; p.R151G	c.451A>G; p.R151G	
TR36	14	F	14	No	No	ESRD at age 6	CAPD, HD, TX	c.681 G>A; p.E227E	c.1015 G>A; p.G339R	rs222753 (h)
TR37	29	F	106	Yes	No	ESRD at age 16	CAPD	c.18_21del[GACT;p.T7X7	c.470 G>A; p.G157D	rs222753 (h)
TR121	20.5	M	13	No	Only child	ESRD at age 11	CAPD, HD	c.140+1 G>T	c.140+1 G>T	rs76153698 (H)
TR11	13	F	18	Yes	Yes	ESRD at age 9	Preemptive Tx	c.681 G>A; p.E227E	c.681 G>A; p.E227E	rs222753 (H)
TR12	7	F	24	Yes	Sib of TR 12	RI		c.681 G>A; p.E227E	c.681 G>A; p.E227E	rs222753 (H)

CAPD continuous ambulatory peritoneal dialysis, *ESRD* end-stage renal disease, *HD* hemodialysis, *RI* renal insufficiency, *Tx* transplantation, *H* homozygote, *h* heterozygote, *RRT* renal replacement therapy
^a Position based on the GenBank NM_004937.2 sequence (HGVS nomenclature). The “rs” numbers correspond to dbSNP (<http://www.ncbi.nlm.nih.gov/snp/>) accession numbers

Fig. 1 Sequence electropherograms of exon 5 of the *CTNS* gene for c.451 A>G variant. The wild-type sequence in a healthy control is shown in the *left* electropherogram (a, *arrow*); the affected individual has a homozygous c.451 A>G variation (b, *arrow*)



Results

Twelve patients (seven male; five female) from ten families were evaluated. Patients’ ages ranged from 7 to 29 years; age at diagnosis was 1 month to 9 years. Consanguinity was reported for six families, and in two families there were two affected siblings. All patients were put on cysteamine bitartrate treatment at diagnosis. Six patients reached ESRF; one is receiving PD, three are on HD, and two have undergone renal Tx. Of the remaining six patients, three

had varying degree of renal failure and three had proteinuria at the time of the study (Table 1). Before sequencing, all patients were tested for the 57-kb deletion and it was not found in any of them. Analysis of the ten coding exons of *CTNS* revealed the presence of nucleotide variations in all patients. Thirteen different variants (Table 1) were identified in the 12 patients; four were already referenced in the dbSNP (<http://www.ncbi.nlm.nih.gov/snp/>) (rs161400, rs1800528, rs222753, and rs76153698). The others were one deletion (10 kb), one small deletion (4 bp), four missense

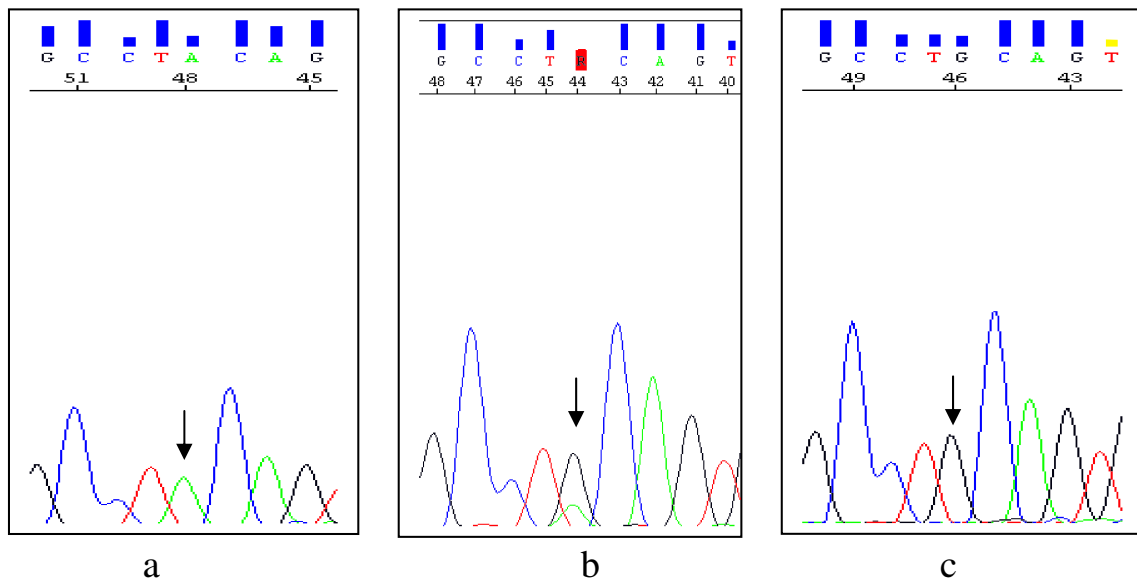


Fig. 2 Sequence electropherograms of exon 6 of the *CTNS* gene for c.518A>G variation. The wild-type sequence in a healthy control is shown in the *left* electropherogram (a, *arrow*). Parents are heterozygous (b, *arrow*); the affected individual has a homozygous c.518A>G variation (c, *arrow*)

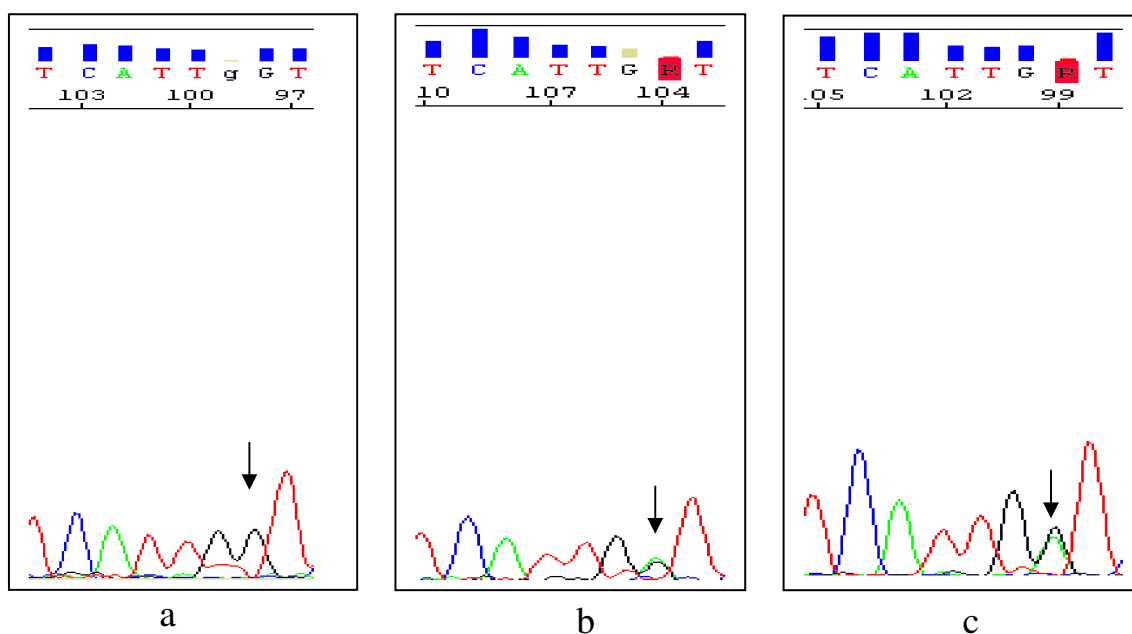


Fig. 3 Sequence electropherograms of exon 6 of the *CTNS* gene for c.470 G>A variation. The wild-type sequence in a healthy control is shown in the left electropherogram (a, arrow); the father is heterozygous (b, arrow); the affected individual has a heterozygous c.470 G>A variation (c, arrow)

variants, two potential splice-site modifications, and a nucleotide substitution in a potential branch-point site of intron 4.

Newly identified missense variations c.451A>G, c.518A>G, and c.470 G>A were searched in 100 healthy Turkish controls by direct sequencing; none of these three variants was found in healthy Turkish controls (Figs. 1–3). We also demonstrated segregation in two families in which DNA was available (Figs. 2 and 3).

The potential effects of the nucleotide changes on cystinosin are listed in Table 2.

Discussion

The diagnosis of cystinosis is confirmed by demonstrating markedly elevated cystine levels in polymorphonuclear leucocytes [1, 22]. Detection of corneal crystals by slit-lamp examination is virtually diagnostic of cystinosis in patients with Fanconi syndrome. However, corneal crystals may not develop until 1–1.5 years of age, so this finding is not sensitive for early diagnosis that, along with diligent compliance with cystine-depleting treatment, determines prognosis. Another determinant is genetic predisposition. Infantile nephropathic cystinosis is associated with two severe *CTNS* mutations, including deletions, insertions, nonsense, missense, and splicing mutations, that cause complete abolition of cystine transport. The adolescent and ocular forms generally have one severe and one mild

mutation, leading to reduced cystine transport [1, 5, 23]. Molecular studies have revealed that 50–60% of northern European and North American patients with cystinosis have a common 57-kb deletion that affects the first ten exons of the *CTNS* gene, consistent with a founder effect [11, 13–16]. On the other hand, the 57-kb deletion has been detected with a much lower frequency in Italians, French Canadians, and Mexicans [12, 18, 20]; the carrier rate was only 17% in Italians. HGMD (<http://www.hgmd.cf.ac.uk/ac/index.php>) describes approximately 100 mutations in the *CTNS* gene.

This report represents the first description of the genetic basis of cystinosis in Turkish patients. Our data reveal that the Turkish cystinosis population has novel genetic characteristics. Specifically, we did not detect the northern European 57-kb deletion in any Turkish patient. Of 13 different variants identified, five were novel, such as three missense variants [c.518A>G (p.Y173C), c.451A>G (p.R151G), c.470 G>A (p.G157D)], a new gross deletion (c.62-1083_551del10217bp), removing nucleotides between intron 3 and exon 8, and the sequence variation in a potential consensus branch point sequence (c.141-22a>g). Although no functional studies have been performed, the amino-acid changes p.Y173C, p.R151G, and p.G157D are very likely to be causative mutations based on formal criteria, evolutionary conservation, and absence in healthy controls, as well as prediction software (Figs. 1–3 and Table 2). The sequence variation c.141-22a>g may disturb a consensus sequence for a branch point and interfere with correct or efficient splicing [24]. Regular software to predict efficiency of RNA splicing

Table 2 Predicted effects of *CTNS* variants^a

Variant ^b	Prediction	Reference
Deletions		
c.18_21delGACT; p.T7FX7	Frameshift	[8]
c.62-1083_551del10217bp	Deletion from intron 3 to exon 8	This study
Missense variants		
	Blossum 62	PolyPhen
	PSIC score	PHAT score
c.451A>G; p.R151G	2.328	NA
c.518A>G; p.Y173C	3.048	-1
c.470 G>A; p.G157D	2.267	NA
c.779 C>T; p.T260I	1.072	NA
c.1015 G>A; p.G339R	2.285	-5
	Panther	PMut
	subPSEC	NN output
	Reliability	Reliability
c.451A>G; p.R151G	-4.49143	0.7813
c.518A>G; p.Y173C	-6.882	0.6686
c.470 G>A; p.G157D	-5.63012	0.6911
c.779 C>T; p.T260I	-2.13647	0.6573
c.1015 G>A; p.G339R	-5.3956	0.8416
	SIFT	
	Not Tolerated	5
	Not Tolerated	3
	Not Tolerated	3
	Tolerated	3
	Not Tolerated	6
	[9]	
Splicing variants		
	BDGP	NetGene2
	Score	NN score
c.140+1 G>T	1>0	0.998>0
c.504 G>A	No effect	No effect
c.681 G>A	0.99>0	0.992>0.845
c.970+15 G>A	No effect	No effect
c.970+70 C>T	No effect	No effect
	Confidence	
	1>0	
	No effect	
	1>0.904	
	No effect	
	No effect	
	rs1800528	
	[24]	
	rs76153698	
	rs222753	

^a Abbreviations: Align, Prediction based on the alignment; *Annot*, Prediction based on the gene annotation; *BDGP*, Berkeley Drosophila Genome Project; *NA*, Not Available; *NN*, Neuronal Network; *PHAT*, Predicted Hydrophobic And Transmembrane; *PSIC*, Position-Specific Independent Count; *subPSEC*, substitution Position-Specific Evolutionary Conservation
^b Position based on the GenBank NM004937.2 sequence (HGVS nomenclature). The “rs” number corresponds to the dbSNP accession

URLs:

- BDGP: http://www.fruitfly.org/seq_tools/splice.html
- dbSNP: <http://www.ncbi.nlm.nih.gov/snp/>
- NetGene2: <http://www.cbs.dtu.dk/services/NetGene2/>
- Panther: <http://www.pantherdb.org/tools/csnpscoreForm.jsp>
- PMut: <http://mmb2.pcb.ub.es:8080/PMut/>
- PolyPhen: <http://coot.embl.de/PolyPhen/>
- Sift: http://blocks.fhcrc.org/sift/SIFT_seq_submit2.html

does not exist for branch sites to our knowledge. Confirmation that this variant has an effect on splicing analysis on the RNA level is required. [25].

Of the eight previously reported variants, four had been associated with cystinosis [8–10, 26] and four were referenced in the dbSNP. The variant c.140+1 G>T has been described as 479+1 G>T according to old nomenclature; it affects a canonical splice site and results in loss of cystinosin function [8]. The variant c.1015 G>A (p.G339R) abolishes cystine transport in an in vitro functional model [9, 10]. The variant 4-bp deletion c.18_21del GACT (p.T7FX7) was described by Town et al. [8] and reported in different populations with cystinosis. The variant c.681 G>A (p.E227E), described in an Arabic population, is located in an exon–intron boundary and disturbs normal splicing [26].

In our study, the most common variants identified were rs222753 at around 45%, as described in the dbSNP; and c.681 G>A; pE227E at around 29%, as a disease-causing variant [26]. Interestingly, the consanguinity of TR2, TR3, TR6, TR7, TR11, and TR12 is supported by the presence of homozygous variants. However, for patients TR4, TR5, and TR37, heterozygous variants are present despite parental consanguinity. Clinically, the patient homozygous for the 10-kb deletion (TR3) followed a severe course and progressed to ESRF at 10 years of age. Patients TR6 and TR7, homozygous for the new missense variants c.518A>G (p.Y173C) and c.451A>G (p.R151G), both had moderate disease courses, reaching adolescence with proteinuria but no renal failure. Patient TR121, homozygous for the known variant c.140+1 G>T that affects a canonical splice site, had a severe disease course [8]. The siblings (TR11 and TR12) homozygous for c.681 G>A (pE227E) exhibited a severe disease course but were the most noncompliant patients, which might be related to disease course. TR1, compound heterozygous for a new missense variant c.451A>G (p.R151G) and a known missense variant c.1015 G>A (p.G339R), had a mild disease course, with good compliance and largely intact renal function at age 12. On the other hand, TR36, compound heterozygous for the c.681 G>A (p.E227E) and the same known missense variant (c.1015 G>A; p.G339R), is noncompliant and has experienced severe disease, with ESRF at approximately 10 years of age; she was recently transplanted with her mother's kidney.

The discrepancy in disease course in patients TR2 and TR 37 could be due to the different variants in the second allele as well as compliance to cysteamine treatment. TR2, homozygous for a known 4-bp deletion c.18_21delGACT; p.T7FX7, has severe disease with liver involvement. This deletion has been found in different populations and with widely variable disease severities [8, 9]. TR37 was compound heterozygous for a new missense mutation c. 470 G>A (p.G157D) inherited from her father (Fig. 3b)

and a known deletion c.18_21delGACT (p.T7FX7) inherited from her mother. The patient had a fairly good course but progressed to end-stage renal disease (ESRD) at 16 years. Siblings TR4 and TR5 were compound heterozygous for a known splice-site variant c.681 G>A (p.E227E) and a new variant c.141-22a>g. These siblings had a completely different courses. Although TR4 was diagnosed at age 13 months, he was lost to follow-up for a long period and progressed to ESRD at age 9.5 years. On the other hand, TR5 had adequate management and follow-up and did not require renal replacement treatment as of age 17.5 years. These observations confirm once again the key role of early diagnosis and adequate cysteamine treatment in the course of cystinosis. From the genetic point of view, our findings support previous data on genotype–phenotype correlations of cystinosis patients [1, 5, 23].

In summary, we show that Turkish cystinosis patients have different disease-causing variants of *CTNS* compared with European and North American patients. In light of our results, it seems that toward to Mediterranean region, the frequency of the 57-kb deletion decreases. In northern Europe and North American studies, the frequency approximates 50–70%, whereas it decreases to 17% in Italy [18] and is absent in this Turkish cohort. Our data once more confirm the wide mutational spectrum of the *CTNS* gene. Data provide a basis for further molecular diagnosis in the Turkish population.

Acknowledgment We gratefully acknowledge Prof. Dr. Elena Levchenko for her advice and help in completing the genetic analysis and the critical reading of the manuscript. Hacettepe University Nephrogenetics Laboratory was established by Hacettepe University Infrastructure Project (Project No: 06A101008)

References

- Gahl WA, Thoene JG, Schneider JA (2002) Cystinosis. *N Engl J Med* 347:111–121
- Schneider JA, Rosenbloom FM, Bradley KH, Seegmiller JE (1967) Increased free-cystine content of fibroblasts cultured from patients with cystinosis. *Biochem Biophys Res Commun* 29:527–531
- Gahl WA, Bashan N, Tietze F, Bernardini I, Schulman JD (1982) Cystine transport is defective in isolated leukocyte lysosomes from patients with cystinosis. *Science* 217:1263–1265
- Sonies BC, Almajid P, Kleta R, Bernardini I, Gahl WA (2005) Swallowing dysfunction in 101 patients with nephropathic cystinosis: benefit of long-term cysteamine therapy. *Medicine (Baltimore)* 84:137–146
- Kalatzis V, Antignac C (2003) New aspects of the pathogenesis of cystinosis. *Pediatr Nephrol* 18:207–215
- Gahl WA, Balog JZ, Kleta R (2007) Nephropathic cystinosis in adults: natural history and effects of oral cysteamine therapy. *Ann Intern Med* 147:242–250
- Gahl WA, Reed GF, Thoene JG, Schulman JD, Rizzo WB, Jonas AJ, Denman DW, Schlesselman JJ, Corden BJ, Schneider JA (1987) Cysteamine therapy for children with nephropathic cystinosis. *N Engl J Med* 316:971–977

8. Town M, Jean G, Cherqui S, Attard M, Forestier L, Whitmore SA, Callen DF, Gribouval O, Broyer M, Bates GP, van't Hoff W, Antignac C (1998) A novel gene encoding an integral membrane protein is mutated in nephropathic cystinosis. *Nat Genet* 18:319–324
9. Shotelersuk V, Larson D, Anikster Y, McDowell G, Lemons R, Bernardini I, Guo J, Thoene J, Gahl WA (1998) CTNS mutations in an American-based population of cystinosis patients. *Am J Hum Genet* 63:1352–1362
10. Kaletzis V, Nevo N, Cherqui S, Gasnier B, Antignac C (2004) Molecular pathogenesis of cystinosis: effect of CTNS mutations on the transport activity and subcellular localization of cystinosin. *Hum Mol Genet* 13:1361–1371
11. Anikster Y, Shotelersuk V, Gahl WA (1999) CTNS mutations in patients with cystinosis. *Hum Mutat* 14:454–458
12. McGowan-Jordan J, Stoddard K, Podolsky L, Orrbine E, McLaine P, Town M, Goodyer P, MacKenzie A, Heick H (1999) Molecular analysis of cystinosis: probable Irish origin of the most common French Canadian mutation. *Eur J Hum Genet* 7:671–678
13. Heil SG, Levchenko E, Monnens LA, Trijbels FJ, Van der Put NM, Blom HJ (2001) The molecular basis of Dutch infantile nephropathic cystinosis. *Nephron* 89:50–55
14. Kalatzis V, Cherqui S, Jean G, Cordier B, Cochat P, Broyer M, Antignac C (2001) Characterization of a putative founder mutation that accounts for the high incidence of cystinosis in Brittany. *J Am Soc Nephrol* 12:2170–2174
15. Kiehntopf M, Schickel J, Gonne B, Koch HG, Superti-Furga A, Steinmann B, Deufel T, Harms E (2002) Analysis of the CTNS gene in patients of German and Swiss origin with nephropathic cystinosis. *Hum Mutat* 20:237
16. Kleta R, Anikster Y, Lucero C, Shotelersuk V, Huizing M, Bernardini I, Park M, Thoene J, Schneider J, Gahl WA (2001) CTNS mutations in African American patients with cystinosis. *Mol Genet Metab* 74:332–337
17. Kalatzis V, Cohen-Solal L, Cordier B, Frishberg Y, Kemper M, Nuutinen EM, Legrand E, Cochat P, Antignac C (2002) Identification of 14 novel CTNS mutations and characterization of seven splice site mutations associated with cystinosis. *Hum Mutat* 20:439–446
18. Mason S, Pepe G, Dall'Amico R, Tartaglia S, Casciani S, Greco M, Bencivenga P, Murer L, Rizzoni G, Tenconi R, Clementi M (2003) Mutational spectrum of the CTNS gene in Italy. *Eur J Hum Genet* 11:503–508
19. Huizing M, Anikster Y, Fitzpatrick DL, Jeong AB, D'Souza M, Rausche M, Toro JR, Kaiser-Kupfer MI, White JG, Gahl WA (2001) Hermansky-Pudlak syndrome type 3 in Ashkenazi Jews and other non-Puerto Rican patients with hypopigmentation and platelet storage-pool deficiency. *Am J Hum Genet* 69:1022–1032
20. Anikster Y, Lucero C, Touchman JW, Huizing M, McDowell G, Shotelersuk V, Green ED, Gahl WA (1999) Identification and detection of the common 65-kb deletion breakpoint in the nephropathic cystinosis gene (CTNS). *Mol Genet Metab* 66:111–116
21. Vilboux T, Kayser M, Introne W, Suwannarat P, Bernardini I, Fischer R, O'Brien K, Kleta R, Huizing M, Gahl WA (2009) Mutation spectrum of homogentisic acid oxidase (HGD) in alkaptonuria. *Hum Mutat* 30:1611–1619
22. Attard M, Jean G, Forestier L, Cherqui S, van't Hoff W, Broyer M, Antignac C, Town M (1999) Severity of phenotype in cystinosis varies with mutations in the CTNS gene: predicted effect on the model of cystinosin. *Hum Mol Genet* 8:2507–2514
23. Alcantara-Ortigoza MA, Belmont-Martinez L, Vela-Amieva M, Gonzalez-Del Angel A (2008) Analysis of the CTNS gene in nephropathic cystinosis Mexican patients: report of four novel mutations and identification of a false positive 57-kb deletion genotype with LDM-2/exon 4 multiplex PCR assay. *Genet Test* 12:409–414
24. Baralle D, Baralle M (2005) Splicing in action: assessing disease causing sequence changes. *J Med Genet* 42:737–748
25. Taranta A, Wilmer MJ, van den Heuvel LP, Bencivenga F, Bellomo F, Levchenko EN, Emma F (2010) Analysis of CTNS gene transcripts in nephropathic cystinosis. *Pediatr Nephrol* 25:1263–1267
26. Aldahmesh MA, Humeidan A, Almojalli HA, Khan AO, Rajab M, AL-A AA, Meyer BF, Alkuraya FS (2009) Characterization of CTNS mutations in Arab patients with cystinosis. *Ophthalmic Genet* 30:185–189